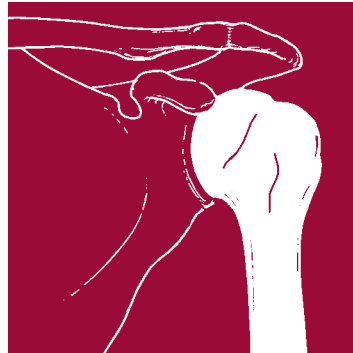



**ZIMMER®
BIGLIANI/
FLATOW®
THE COMPLETE
SHOULDER
SOLUTION**

**Total
Shoulder
Arthroplasty
Surgical
Technique**



zimmer
Confidence in your hands™

BIGLIANI/FLATOW® THE COMPLETE SHOULDER SOLUTION SURGICAL TECHNIQUE

Instruments and surgical technique
developed in conjunction with:

Louis Bigliani, M.D.

Chairman, Department of Orthopaedics

Director, The Shoulder Service

New York Presbyterian Hospital

Columbia-Presbyterian Center

New York, New York

Evan Flatow, M.D.

Chief of Shoulder Surgery

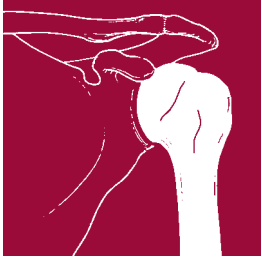Mount Sinai Medical Center

New York, New York

CONTENTS

SURGICAL TECHNIQUE FOR *BIGLIANI/FLATOW* SHOULDER SYSTEM

Patient Positioning	2
Incision and Exposure	2
Humeral Preparation	3
Glenoid Preparation	9
Humeral Head Selection	15
Expanded Glenoid Options	16
Implantation	18
Humeral Head Removal	25
Closure	25
Postoperative Management	25



PATIENT POSITIONING

Patient positioning is especially important in total shoulder surgery (Fig. 1). Place the patient in a semi-beach-chair position. Use a head rest that allows for the superior part of the table to be removed. Place two towels under the spine and the medial border of the scapula to raise the affected side. Raise the head of the table approximately 25-30 degrees to reduce venous pressure. Attach a short arm board to the table, or use another arm support method that will allow the arm to be raised or lowered as necessary throughout the procedure.

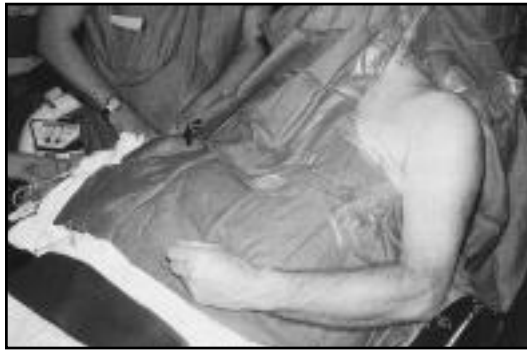

Fig. 1

INCISION AND EXPOSURE

First, mark the coracoid process. Then mark the line of the incision, beginning at the clavicle just lateral to the coracoid process. Extend the line along the deltopectoral groove to the area of the mid-humerus (Fig. 2). Then make the incision following the line. Undermine the skin flaps to improve exposure. Dissect subcutaneous tissue from the deltoid fascia, and



Fig. 2

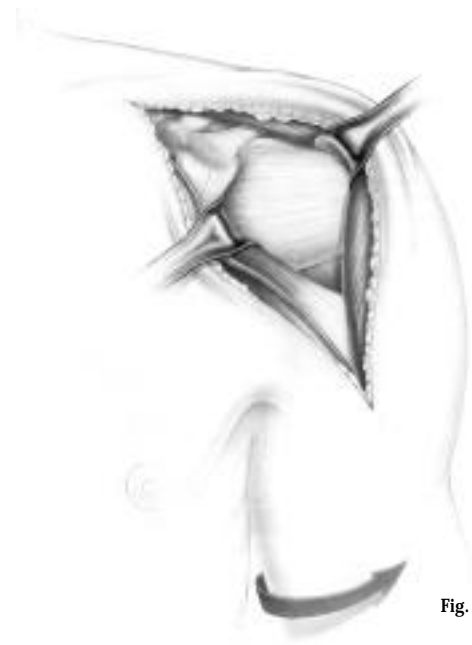

Fig. 3

expose the deltoid and pectoralis major muscles. Retract the skin by placing Gelpi retractors about one-third of the way down, and one-third of the way up. Develop the deltopectoral interval, retracting the pectoralis major medially and the deltoid laterally. Identify and dissect the interval between the pectoralis major muscle and the cephalic vein. Retract the cephalic vein either medially or, preferably, laterally as this will minimize bleeding from the deltoid muscle or cephalic vein. Release the upper 1cm-2cm of the insertion of the pectoralis major tendon, being careful to avoid the long head of the biceps tendon. In very tight shoulders, the pectoralis may need to be completely released. Tag the pectoralis major muscle with a suture so it can be easily identified for later reattachment. Reposition the distal medial retractor under the pectoralis major muscle.

Release any adhesions between the deltoid and strap muscles (coracobrachialis and short head of biceps) and develop a plane between the strap muscles and the humerus. Reposition the proximal medial retractor under the strap muscles (Fig. 3).

Sweep the bursa off the humeral head and the greater tuberosity. Then expose the superior portion of the subacromial space by resecting the leading edge of the coracoacromial ligament. Identify the superior and inferior margins of the subscapularis tendon. Divide the tendon just medial to the bicipital groove and remove it from the lesser tuberosity. Being careful inferiorly to avoid the axillary nerve, retract the subscapularis medially, exposing the articular surface of the humeral head.

It is very important to maintain as much length of the subscapularis muscle as possible. Remove the capsule and subscapularis tendon as a unit laterally from the humerus. Do this as close as possible to the humeral neck to avoid injury to the axillary nerve. External rotation of the humerus is helpful. In cases where there is a large inferior osteophyte on the humeral head, it is especially important to dissect the capsule off the neck of the humerus laterally as the axillary nerve is on the medial and inferior aspect of the osteophyte. Medially, at the glenoid rim, the capsule and labrum can be separated from the subscapularis tendon. This will facilitate lateral mobilization.

HUMERAL PREPARATION

The goal in replacing the humeral head is to place a prosthetic articular surface precisely on the proximal humerus as it would have been before the destructive arthritic process began. The relationship among bony anatomy, rotator cuff insertions, and soft tissue tension must all be considered.

Technique Tip: To facilitate access to the humeral canal, the shoulder should be off the table. To accomplish this, push the elbow back and externally rotate the arm.

REAM HUMERAL CANAL

Dislocate the humeral head by externally rotating and extending the humerus. If necessary, place a metal finger inferiorly between the humerus and the glenoid. Removal of capsule from the inferior aspect of the humeral neck may be needed to achieve dislocation. Before reaming the canal, it is important to remove all anterior or inferior osteophytes so that the true anatomical neck (junction of the articular cartilage and cortical bone) can be determined.

Attach a Short Intramedullary Reamer with a trocar point to the Ratchet T-handle. There are three positions marked on the collar of the T-handle: FORWARD, LOCKED, and REVERSE. To ream the starter hole, use the FORWARD position. Short Intramedullary Reamers are available in diameters of 6mm, 7mm, and 8mm, and the appropriate size should be chosen for the patient's humeral canal. Place the trocar tip of the reamer just posterior to the bicipital groove (Fig. 4) and ream a starter hole. A mallet may be used to start the hole in hard bone.

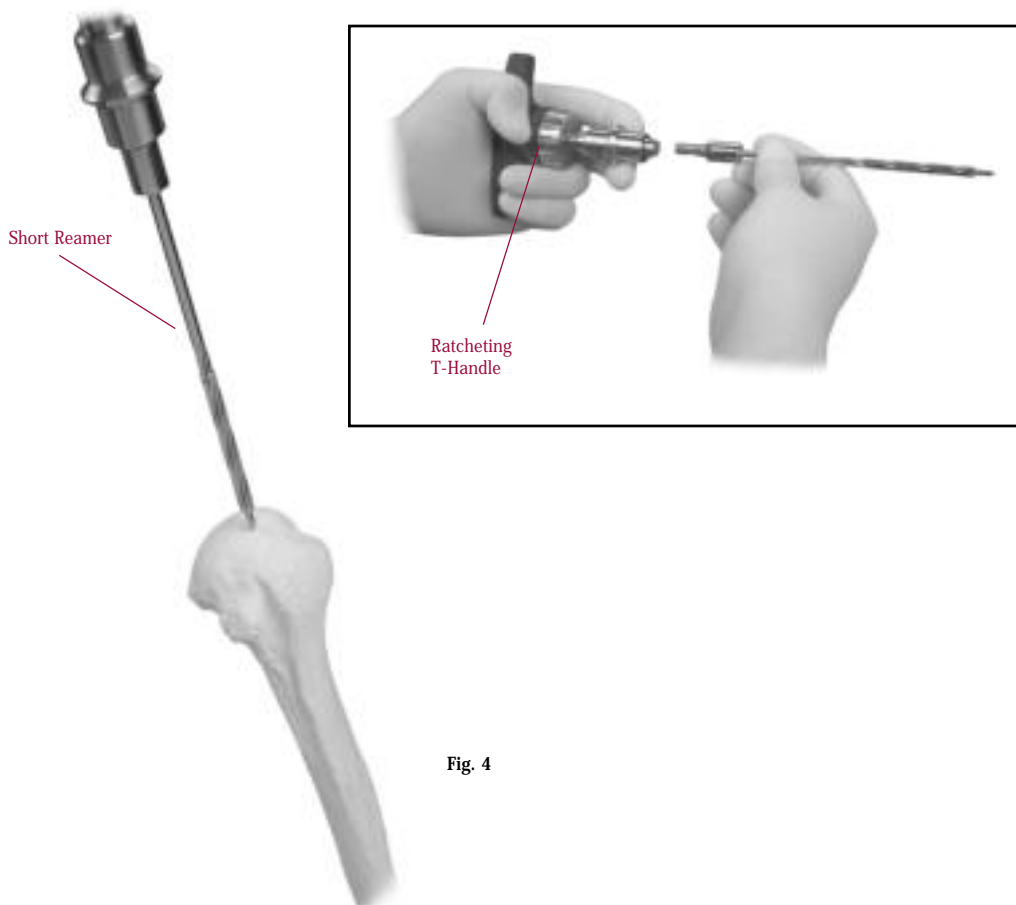
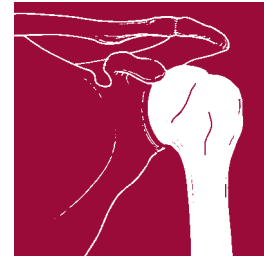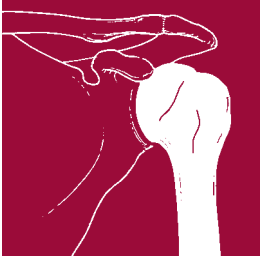


Fig. 4



Attach the T-handle to the longer, blunt-tipped Intra-medullary Tapered Reamer of the same diameter and begin manually reaming the humeral canal. Use progressively larger reamers in 1mm increments until resistance is felt from cortical contact in the canal (Fig. 5). Continue reaming to the appropriate depth as indicated on the reamer shaft. The depth corresponds to the implant length chosen. Do not remove cortical bone. These reamers have blunt tips to help guide them down the canal and prevent obstruction into cortical bone. Remove the T-handle, but leave the last reamer in the canal to interface with the Humeral Head Cutting Guide (Fig. 6).

Note: If using a 60mm length stem, use only the Short Intra-medullary Reamers. Use the Intra-medullary Tapered Reamers for 110mm monoblock stems. Ream until the flutes are buried in the bone.

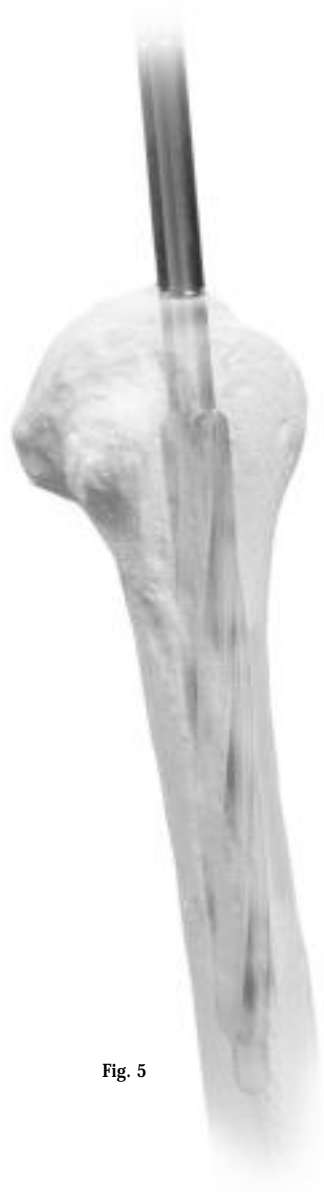

Fig. 5

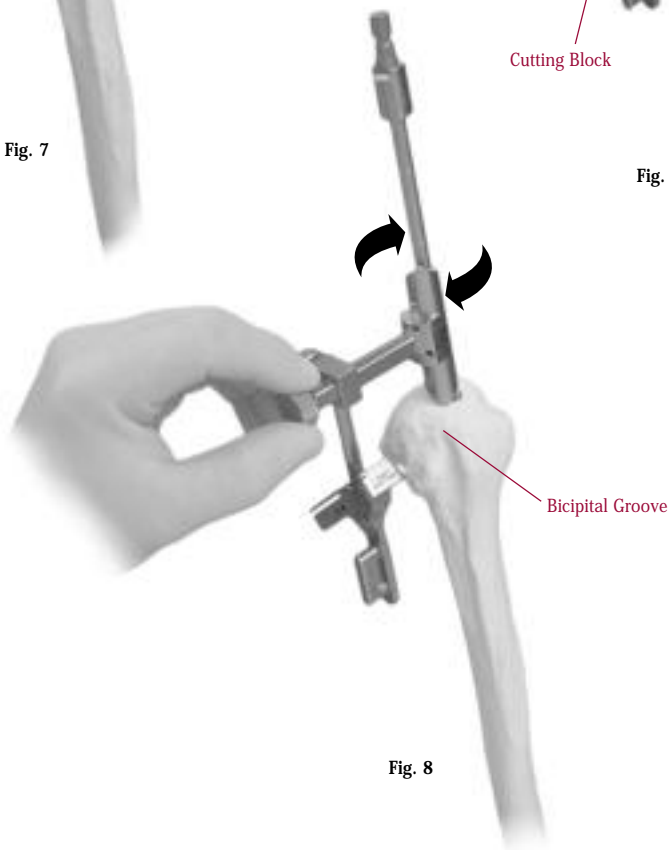
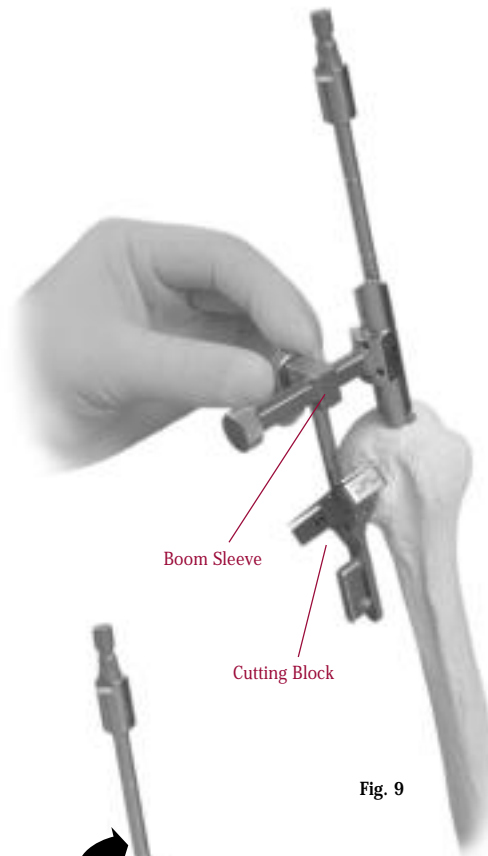
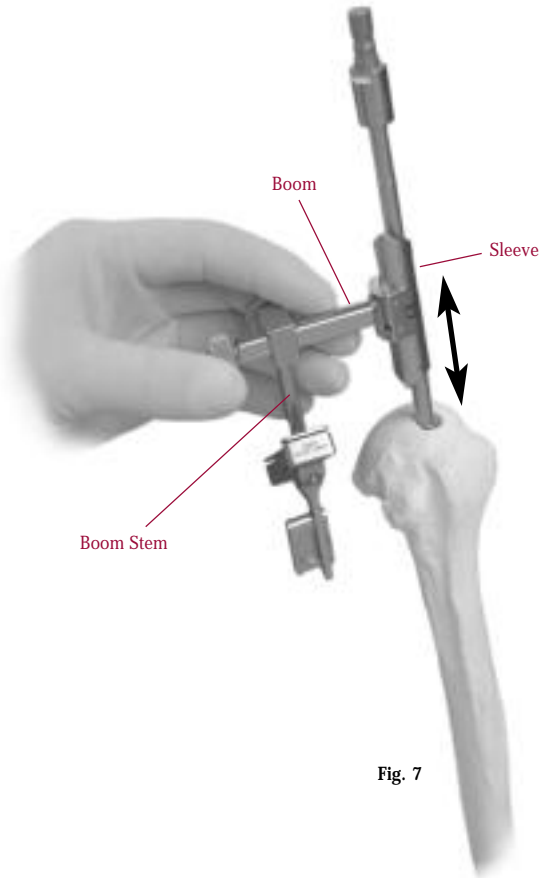
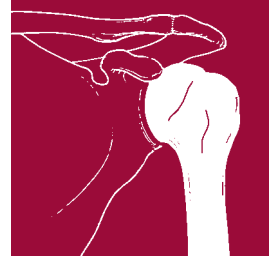

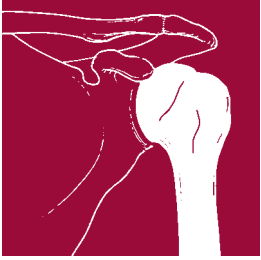
Fig. 6

RESECT HUMERAL HEAD

Assemble the Humeral Head Cutting Guide for either a right or left configuration. (See “How to Assemble the Humeral Head Cutting Guide” on next page.) Slide the boom sleeve over the reamer shaft (Fig. 7). Adjust the depth of cut by moving the sleeve up or down on the reamer shaft. Rotate the sleeve on the reamer shaft

until the point is approximately in line with the bicipital groove (Fig. 8). Then tighten the first thumb screw, which is located on the end of the boom. Advance the boom stem and cutting block along the boom until the block contacts the bone (Fig. 9). Tighten the second thumb screw, which is located at the junction of the boom and boom stem.





To gauge the retroversion of the cut, insert Alignment Pins into the holes marked 20 degrees and 40 degrees on either the cutting block or boom sleeve (Fig. 10a). Then line up the pins with the forearm to assess the retroversion (Fig. 10b). Retroversion can be adjusted by loosening both thumb screws and rotating the cutting guide about the axis of the Intramedullary Reamer. The forearm should be between the 20 degree and 40 degree pins (Fig. 10c). Then retighten the thumb screws, being sure that the cutting block is again touching the bone (Fig. 10d).

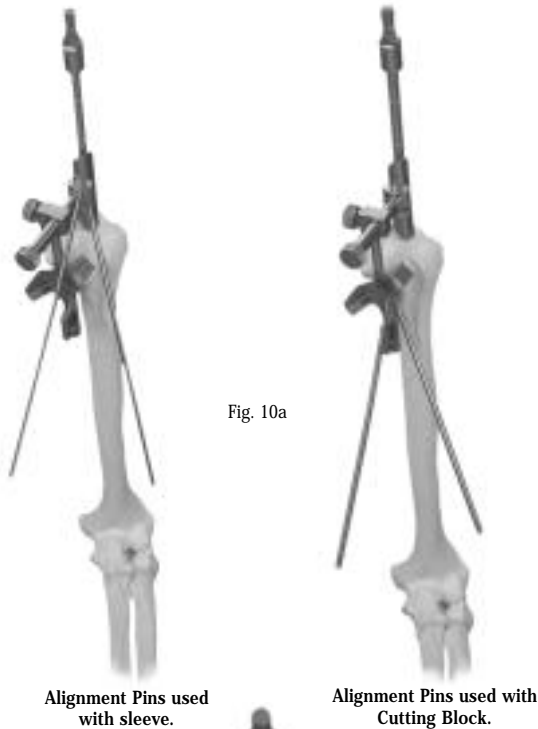


Fig. 10a

Alignment Pins

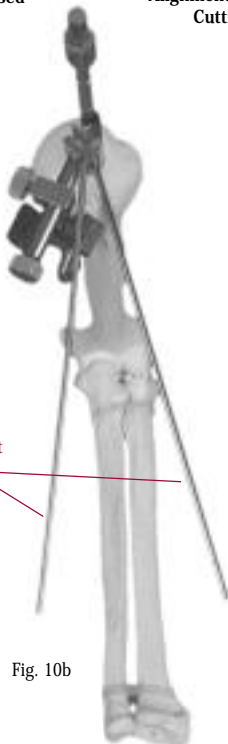
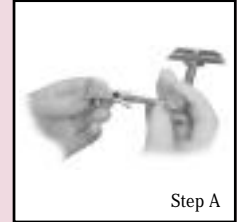
Fig. 10b

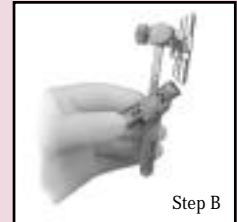
HOW TO ASSEMBLE THE HUMERAL HEAD CUTTING GUIDE

Align the groove on the boom stem with the groove on the cutting block. Push the components together until they snap into place (Step A).



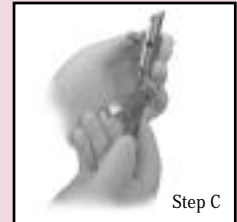
Step A

With the thumb screw at the end of the boom pointed toward you, observe the various "R" or "L" etchings that indicate a right or left configuration. All the etchings that are facing you now should be the same, either "R" or "L" (Step B).

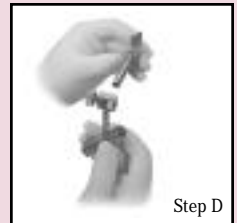

Step B

To change the right/left orientation, remove the thumb screw at the end of the boom (Step C). Then loosen the second thumb screw on the box at the top of the boom stem. Slide the boom stem off the end of the boom. Rotate the sleeve toward you, top to bottom, and reinsert it from the opposite side into the box at the top of the boom stem (Step D). Retighten the thumb screw on the box at the top of the boom stem. Then reinsert and tighten the thumb screw at the end of the boom (Step E). Finally, verify that all the appropriate right or left etch marks are visible when the boom thumb screw is facing you (Step F).



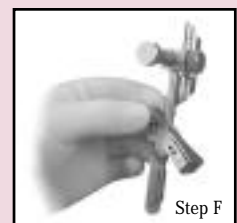Step C



Step D



Step E



Step F

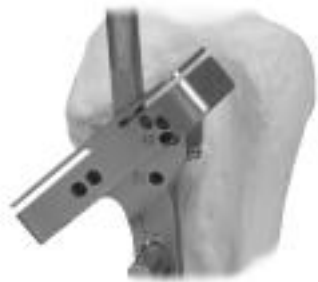

Fig. 10c

20 degree and 40 degree holes are used to check retroversion.



Fig. 10d

Make sure the Cutting Block touches the bone.

Insert the Humeral Head Cutting Guide Fingers into the cutting slots to visualize the path of the saw blade through the bone (Fig. 11). If necessary, loosen the thumb screw at the end of the boom, and move the sleeve up or down to adjust the depth of cut. In some cases, the shoulder capsule may be too tight to accommodate the fingers.

Partially insert a Cutting Guide Pin (5977-56-01) through one of the lateral holes in the cutting block. Fully insert a second pin through one of the medial holes (Fig. 12). If the cortex is very hard, predrill these holes using a drill with a diameter between 2.0mm and 2.7mm.

Loosen both thumb screws on the guide and remove the boom, leaving the cutting block in place. Set the T-handle to the **REVERSE** position. Attach the T-handle to the reamer and remove the reamer from the humeral canal. Then finish impacting the first pin.

Before making the cut, remove the Alignment Pins. It is important to make the cut along the articular surface as this will ensure the correct retroversion on the majority of cases. Care must be taken to avoid cutting into the rotator cuff posteriorly. Use an oscillating saw to resect the humeral head (Fig. 13). Then remove the cutting block.

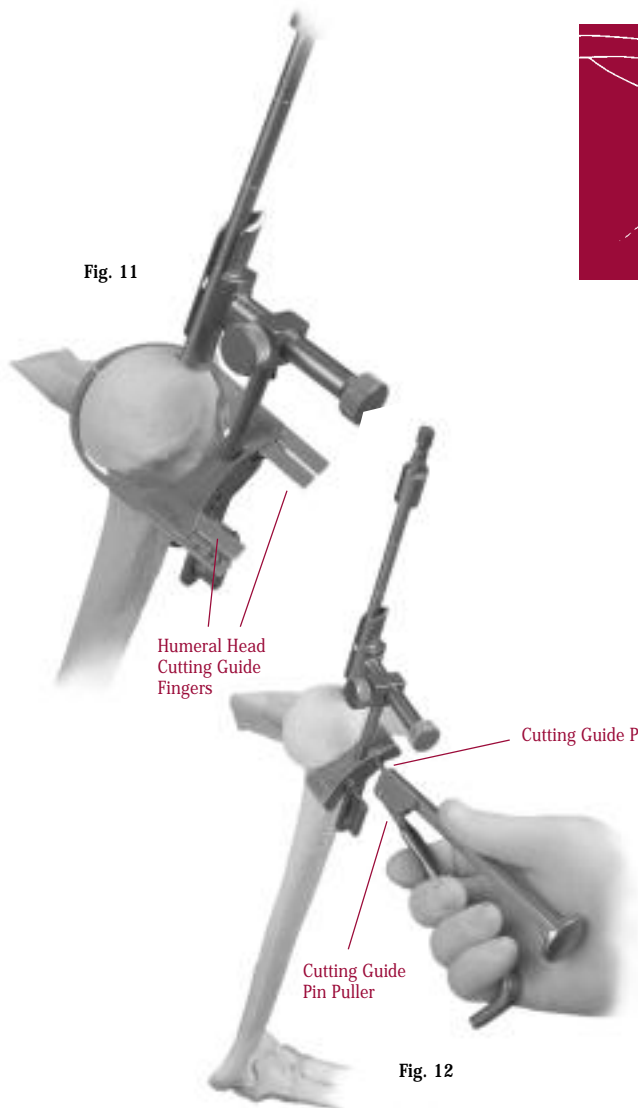
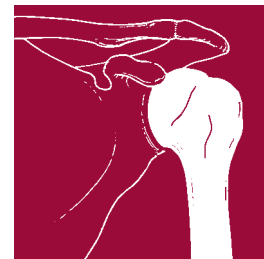

Fig. 11

Fig. 12


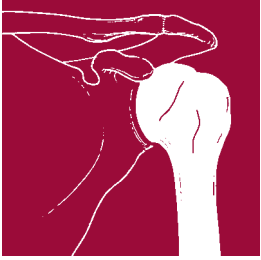


Fig. 13





STEM PROVISIONAL INSERTION

Use the Wrench handle through one of the holes to tighten the white plastic cap on the Humeral Stem Inserter/Extractor. Attach the appropriate Humeral Stem Provisional to the inserter/extractor. (The Humeral Stem Provisional is typically the same size as the largest reamer used.) There are also 20-degree and 40-degree holes on the inserter/extractor to allow for verification of the stem retroversion using the Alignment Pins (Fig. 14).

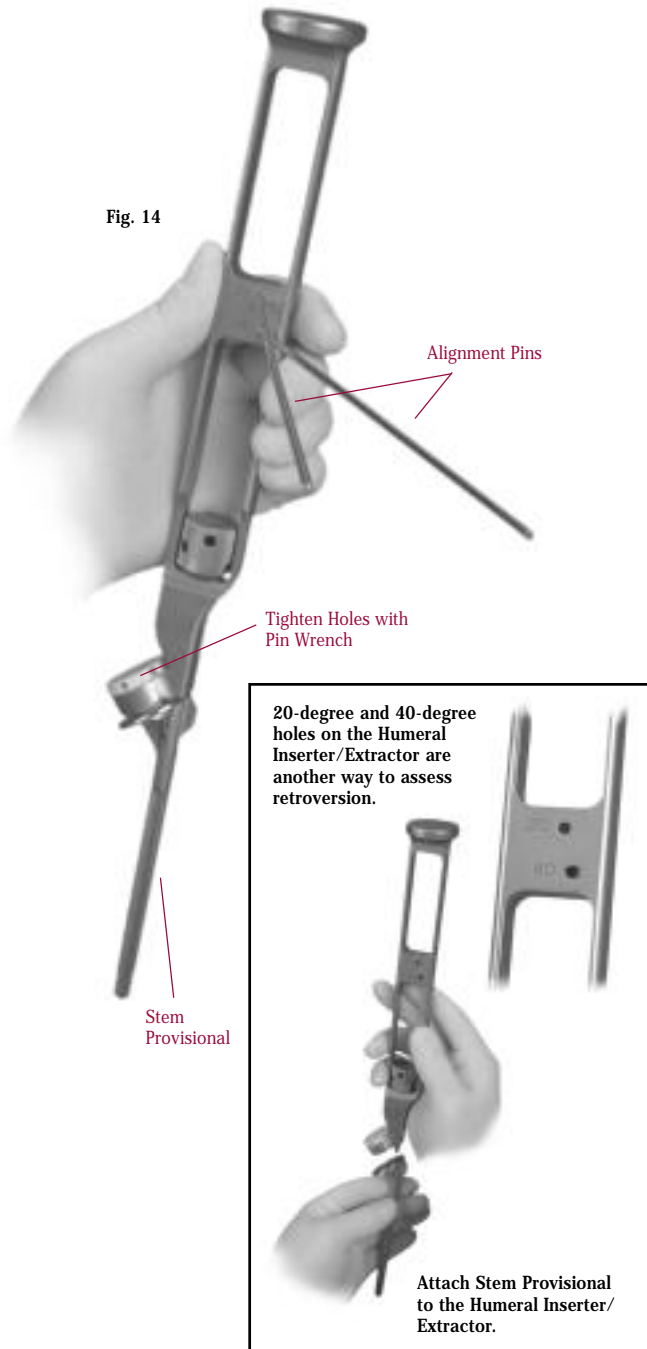


Fig. 14

Technique Tip: To facilitate access to the humeral canal, the shoulder should be off the table. To accomplish this, push the elbow back and externally rotate the arm.

Remove the Alignment Pins before impacting the Humeral Stem Provisional. Insert and impact the Humeral Stem Provisional into the humeral canal until

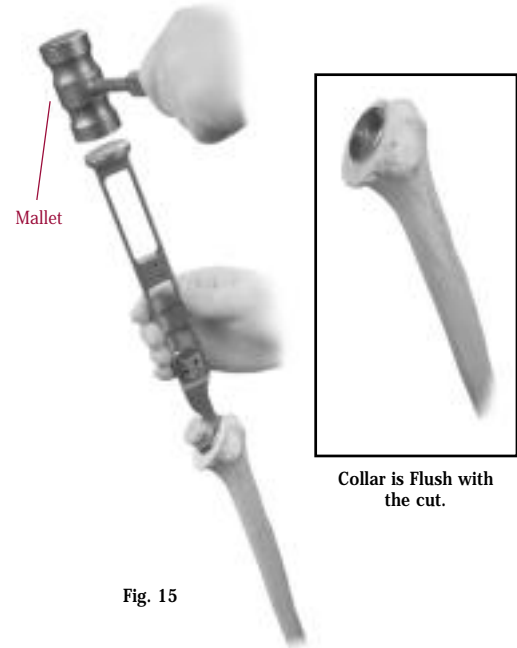


Fig. 15

the collar is flush with the cut surface (Fig. 15). The fins on the Humeral Stem Provisional are self-cutting to prepare a path for the fins on the stem implant. This should place the humeral component in the correct degree of retroversion for that patient.

If the anatomy places the collar of the Humeral Stem Provisional eccentrically, the humeral head will overhang the bony margins on one side and place asymmetric tension on the rotator cuff. This may suggest the use of an offset head for more complete bone coverage. Ideal placement of the humeral head will be achieved when the head is centered relative to the rotator cuff (Fig. 16). The margin of the humeral head

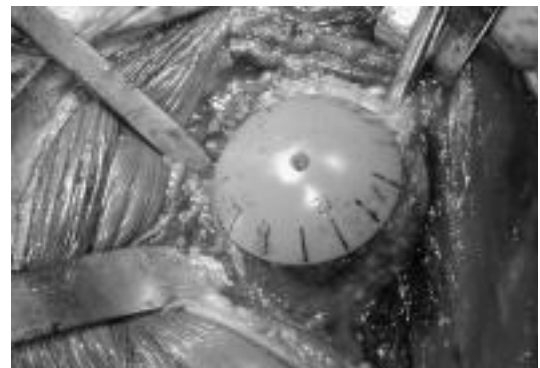


Fig. 16

should rest immediately adjacent to the rotator cuff insertion superiorly on the greater tuberosity, and slightly overhang the calcar medially.

If the humeral component is placed too low, the greater tuberosity will be relatively prominent and impinge under the acromion. This condition can limit the range of motion. In addition, the resulting vector forces will drive the humeral head down against the inferior margin of the glenoid and can contribute to rocking and possible loosening. Therefore, it is important to always check that the superior aspect of the humeral head is above the superior aspect of the greater tuberosity.

If the humeral component is placed too high, the supraspinatus muscle will be under too much tension around the prominent lateral margin of the humeral head. In addition, the uncovered calcar can abut under the inferior margin of the glenoid component and can lead to glenoid rocking and possible loosening.

It is important to keep in mind the very precise relationship of the glenoid articular surface to the tuberosities and rotator cuff insertions so that contracture of the rotator cuff muscles and capsule do not eccentrically load the glenoid. The relationship of this entire complex to the acromion is also critical. The subacromial space should just accommodate the functional rotator cuff and tuberosities.

Use a curette to remove any bone from the center hole of the Humeral Stem Provisional. This will allow for later placement of the Humeral Head Provisional (Fig. 17). Leave the Humeral Stem Provisional in place to help minimize bleeding and protect soft tissue during the glenoid preparation.

For a hemiarthroplasty, advance to page 15.

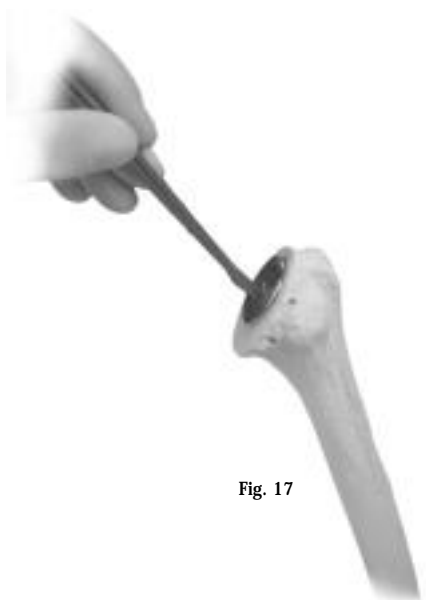

Fig. 17

GLENOID PREPARATION

Precise placement of the glenoid component* is more technically demanding than placement of the humeral component. Before implanting the glenoid component, it is essential to thoroughly evaluate the bony architecture of the glenoid vault. Therefore, it is important to have an axillary radiograph of the glenoid to assess for anterior or posterior wear. If a glenoid radiograph is not possible, a CT or MRI should be obtained. It is important to identify the center of the glenoid vault. To accomplish this, retract the soft tissues both anteriorly and posteriorly to expose the glenoid. A Fukuda Retractor, or a bent glenoid retractor should be placed posteriorly. This will sublaxate the humerus posteriorly and inferiorly. A special pointed Darrach-type Retractor should be placed anteriorly. Strip the capsule from the articular margin of the glenoid. Then place a finger along the anterior glenoid neck to palpate the anteversion of the glenoid face. In most tight shoulders, it may be necessary to release the capsule along the inferior margin of the glenoid, taking care to avoid injury to the axillary nerve. Release of the posterior capsule, which is often already stretched out from chronic posterior humeral subluxation, is not routinely performed to avoid posterior prosthetic instability. In rare cases of extremely tight shoulders some posterior release may be helpful, but this must be individualized and performed with caution.

Osteophytes may disguise the center of the glenoid vault. The surgeon may choose to trim any marginal osteophytes so the glenoid vault can be clearly defined. Sometimes, osteophytes are more pronounced on one side of the glenoid surface than on the other. In such cases, the center of the articular surface, including osteophytes, is not the center of the glenoid vault. It is not necessary to remove all the osteophytes to establish the true center of the glenoid vault; however, if any osteophytes are removed, they should be removed carefully. In particular, removal of posterior osteophytes should be done with caution as the capsular attachments may be more proximal resulting in instability. After removing osteophytes, the center of the humerus can then be centered over the glenoid and the soft tissues balanced.

An inadequate or deformed glenoid vault can create a number of technical problems when implanting a glenoid component. Several bone grafting techniques can be used to enhance the bone stock of an inadequate glenoid vault; however, these procedures are very difficult and each one is unique. If a glenoid replacement is not possible, it is recommended that a hemiarthroplasty be used instead of a total shoulder replacement.

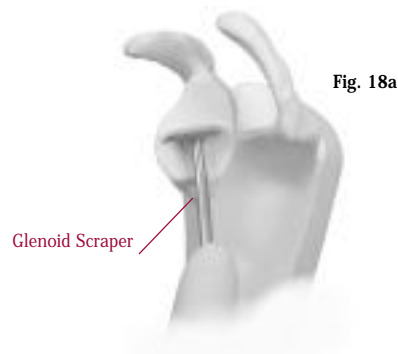


*U.S. Patent 5,928,285



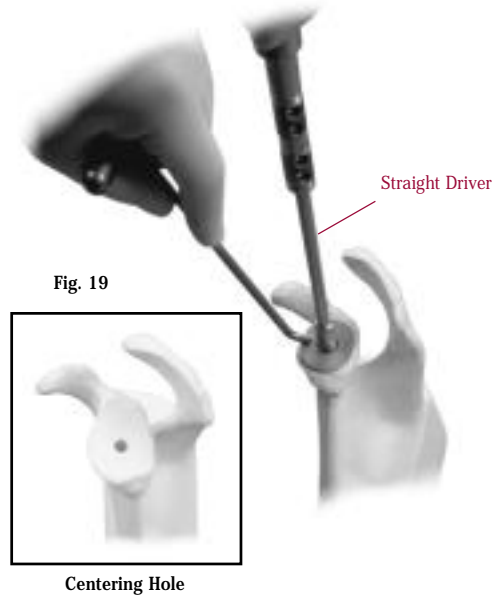
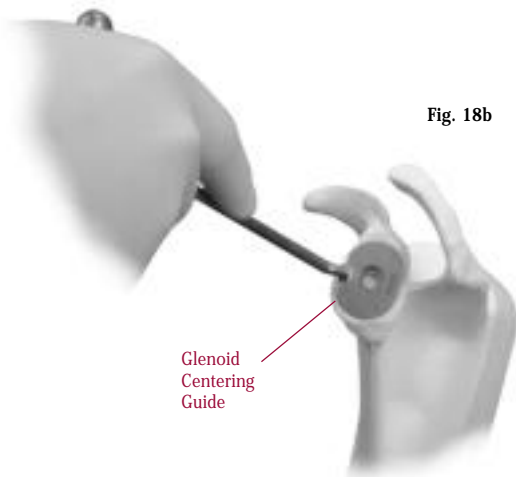
GLENOID SIZING

Use the Glenoid Scraper and Glenoid Planer to remove any remaining cartilage and soft tissue from the glenoid (Fig. 18a). Then use the Glenoid Centering Guides to determine if the glenoid size (**black=40mm, white=46mm, and blue=52mm**) will fit well on the glenoid face. The outer dimensions of the guide match the articular profile of the glenoid implant.



DRILL CENTERING HOLE

When the glenoid size has been selected, apply the appropriately sized Glenoid Centering Guide over the glenoid (Fig. 18b). **Glenoid instruments are color coded by glenoid size (black=40mm, white=46mm, and blue=52mm).** If there is greatly increased glenoid retroversion noted on preoperative radiographs or CT scans, a burr may be used to lower the front of the glenoid slightly. Then use the Glenoid Planer to smooth the area. This will help to avoid perforating the anterior glenoid wall when drilling perpendicular to a retroverted glenoid face. Then apply the appropriate Glenoid Centering Guide. Attach the Glenoid Drill with Stop to the Straight or Angled Driver. The Straight Driver is useful when the glenoid is fully exposed. With limited glenoid exposure, the Angled Driver is recommended. Using power, drill a centering hole through the subchondral bone of the articular surface (Fig. 19).

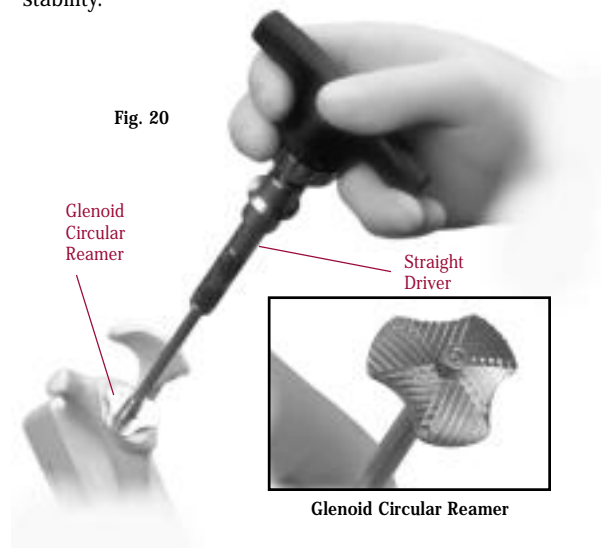


REAM

Attach the Angled Driver or Straight Driver to the Ratchet T-handle. Then attach the appropriate Glenoid Circular Reamer to driver. Insert the nose of the reamer into the centering hole, and ream the glenoid (Fig. 20). To help minimize soft tissue damage, do not use power for reaming. Glenoid reaming is performed to achieve intimate contact between the bone and the spherical undersurface of the glenoid implant.

Reaming may also be performed to compensate for posterior glenoid wear by reaming slightly more anteriorly. In this case, a shallow centering hole is drilled initially, and used to seat the reamer. After reaming, the centering hole may be redrilled to the full depth allowed by the Glenoid Centering Guide.

Overreaming will reduce the depth of the glenoid vault and should be avoided. It is important not to remove too much subcortical bone as this may affect glenoid stability.



FOR KEELED GLENOID COMPONENT

CREATE SLOT

Apply the appropriate size Keeled Glenoid Drill Guide by inserting the tip into the centering hole (Fig. 21). Use the Glenoid Drill with Stop to drill the second hole. An Antirotation Pin or additional Glenoid Drill with Stop may be used to maintain alignment of the guide while the third hole is drilled (Fig. 22). Remove the Keeled Glenoid Drill Guide and apply the appropriate size Keeled Glenoid Slot Guide to the articular

surface (Fig. 23). Use a 5mm high-speed burr to create a vertical slot in the subchondral bone of the articular surface (Fig. 24). Palpate the glenoid vault with the index finger to determine its limits. Then undermine the subchondral bone adjacent to the slot. Use a curette rather than a burr to deepen the slot to the apex of the vault because it is much less likely to penetrate the anterior or posterior cortical wall. Do not attempt to remove the remaining cancellous bone in the vault.

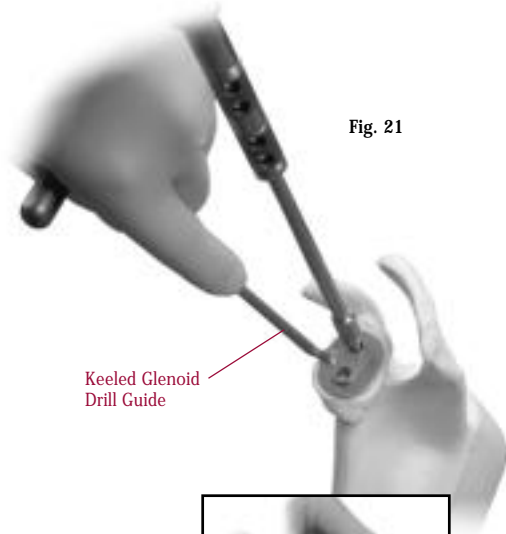
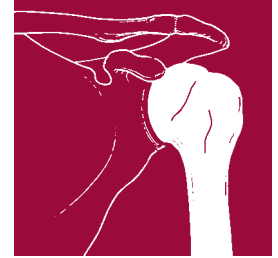

Fig. 21

Keeled Glenoid Drill Guide



Use the Antirotation Pin to maintain alignment.

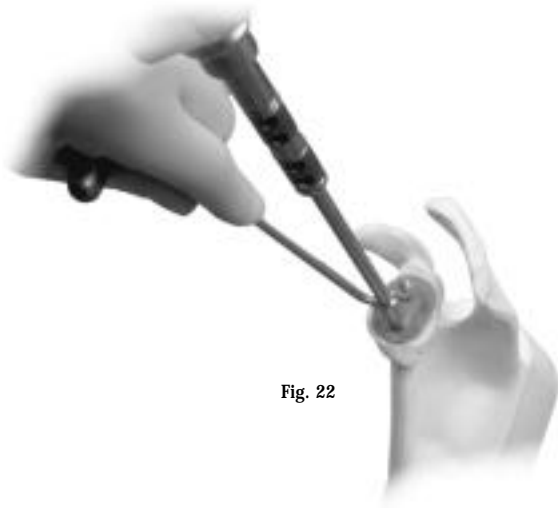

Fig. 22

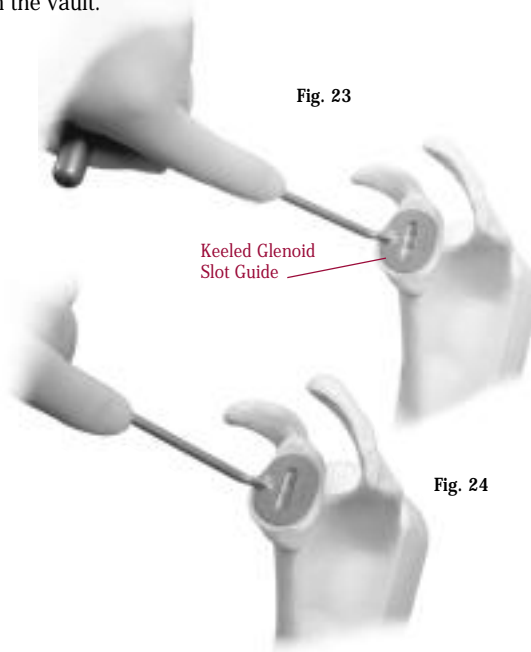


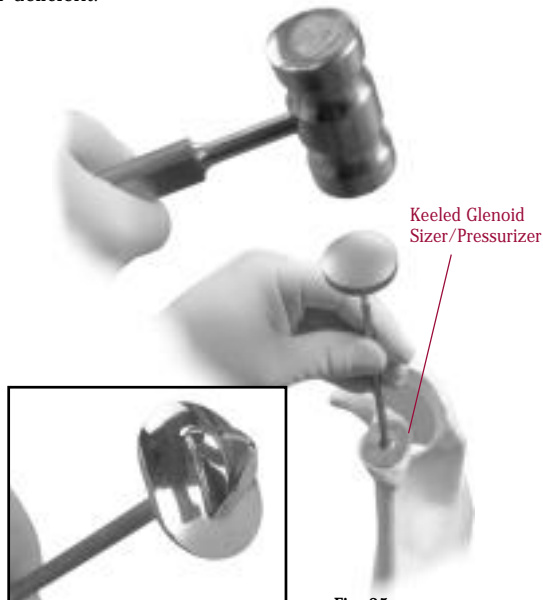
Fig. 23

Keeled Glenoid Slot Guide



Fig. 24

Use a Keeled Glenoid Sizer/Pressurizer to impact the remaining bone in the slot (Fig. 25). This will help ensure an appropriate internal depth and diameter to accept the keel of the glenoid component. This step should be implemented with caution if the bone is soft or deficient.

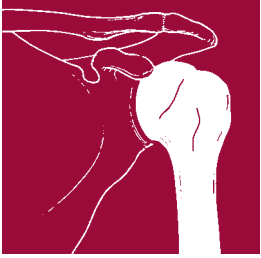


Keeled Glenoid Sizer/Pressurizer



Keeled Glenoid Sizer/Pressurizer

Fig. 25



KEELED GLENOID COMPONENT CONT'D.

If additional glenoid reaming is necessary to improve the glenoid fit or adjust anteversion, attach the appropriate Glenoid Circular Reamer with Keel Locator to either the Angled Driver or Straight Driver. Insert the keel locator into the slot, and use the T-handle to ream the glenoid (Fig. 26).

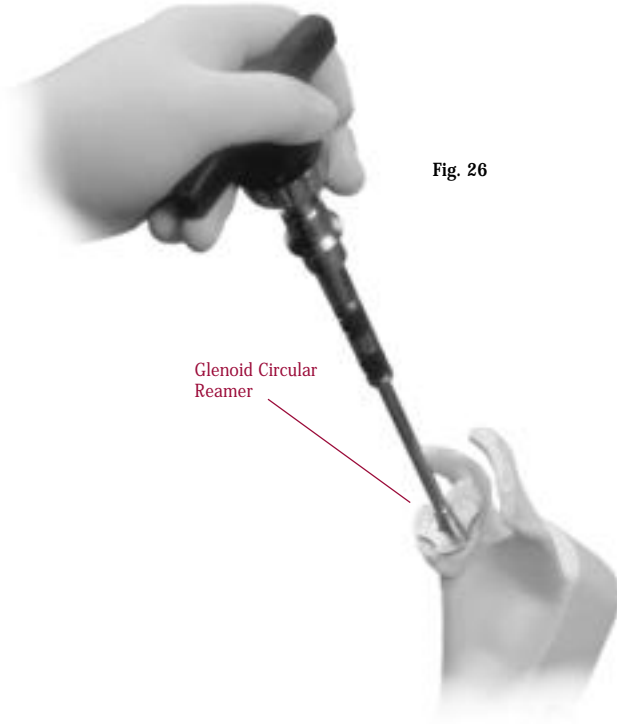
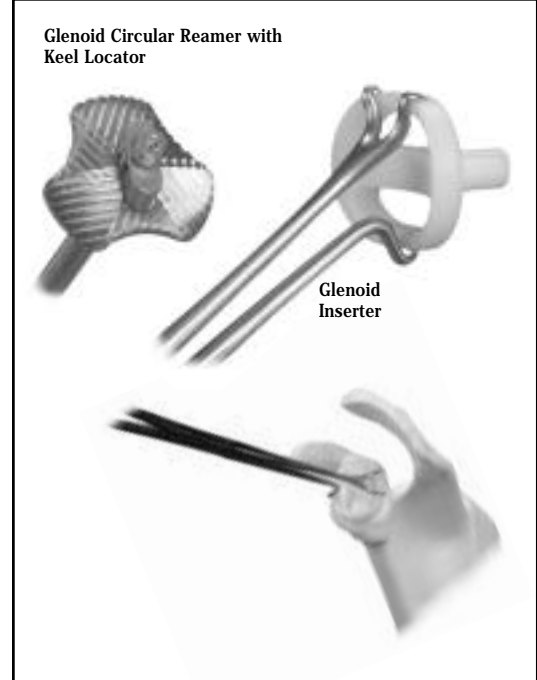


Fig. 26



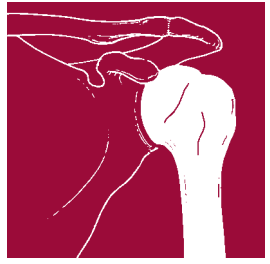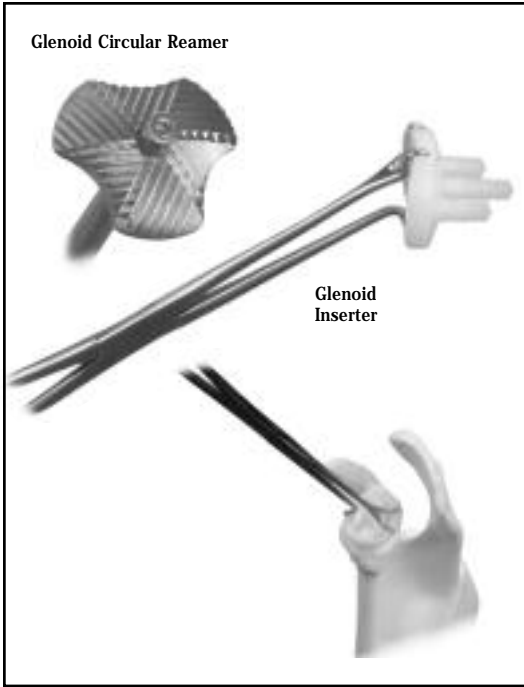
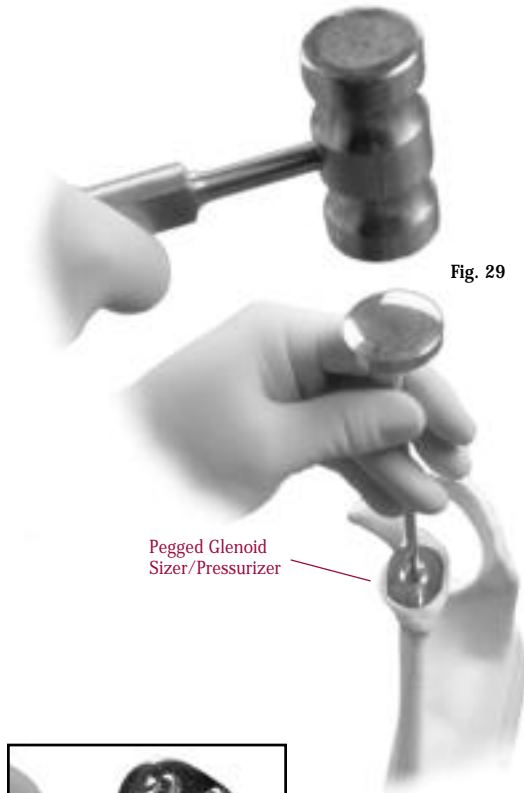
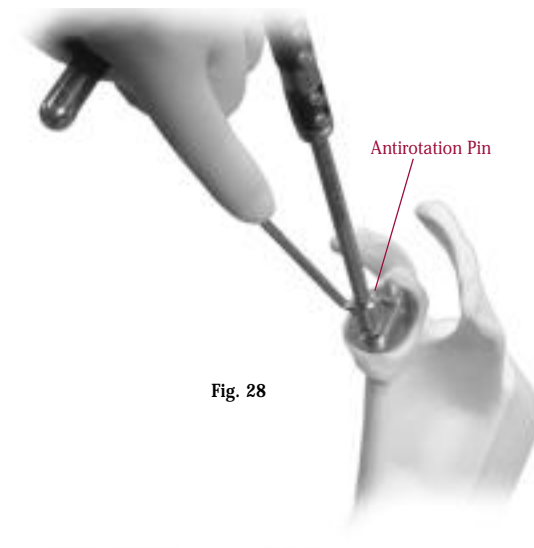
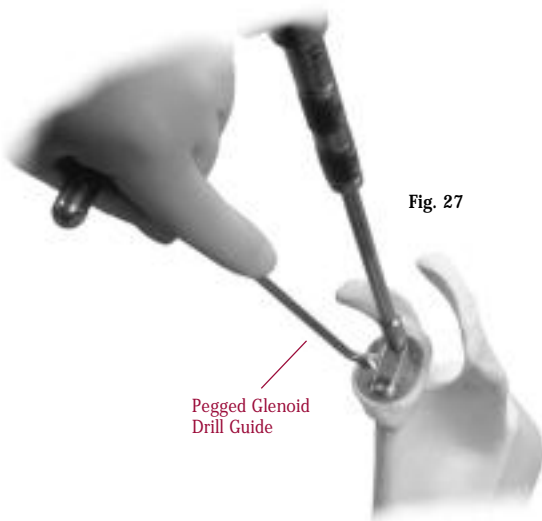
Glenoid Circular Reamer with Keel Locator

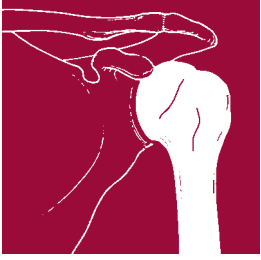
Glenoid Inserter

FOR PEGGED GLENOID COMPONENT

CREATE PEG HOLES

Apply the appropriate size gold Pegged Glenoid Drill Guide to the articular surface by inserting the tip into the centering hole (Fig. 27). Use the Glenoid Drill with Stop to drill the second hole. An Antirotation Pin or additional Glenoid Drill with Stop may be used to maintain alignment of the guide while the third hole is drilled (Fig. 28). Use the Pegged Glenoid Sizer/Pressurizer and mallet to impact the remaining bone in the holes (Fig. 29). If additional glenoid reaming is necessary, insert the Glenoid Circular Reamer into the central hole and manually ream. Additional reaming may lower the articular surface and necessitate re-drilling of the peg holes.





GLENOID TRIAL FIT

Insert the appropriate size Pegged or Keeled Glenoid Provisional. These are solid colored provisional components. The undersurface of the component should seat flush with the articular surface of the bone. Do not trim the pegs or keel of a glenoid component to compensate for an inadequate glenoid vault that cannot accommodate full-size pegs or keel. This can compromise fixation and lead to premature loosening. If the fit of the glenoid component is not appropriate, it may be necessary to reassess reaming and the depth of the peg holes or keel slot.

Position the glenoid component for optimal bony support (Fig. 30). The base of the glenoid component should not overhang the perimeter of the glenoid. Loosening or excessive wear may occur if the glenoid component lacks sufficient bony support.

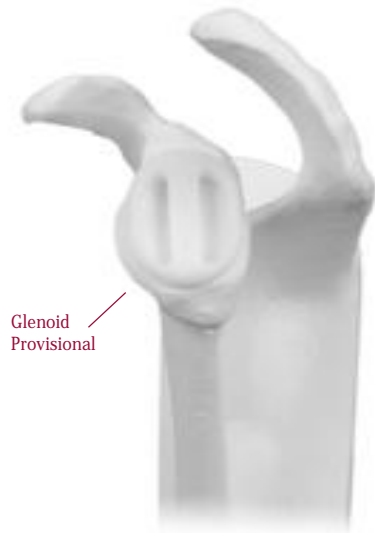

Fig. 30

HUMERAL HEAD SELECTION

Choose a Humeral Head Provisional that best covers the prepared surface of the proximal humerus and fills the rotator cuff circumferentially. Standard or offset heads are available. Insert a metallic Capture Pin into the Humeral Head Provisional (Fig. 31). The resected humeral head can be used as an initial reference for choosing the humeral head size.

Place the Humeral Head Provisional on the Humeral Stem Provisional to the point where the head is at the level of the supraspinatus insertion. The humeral head must at least reach or slightly overhang the calcar medially (Fig. 32). If using an offset head, rotate the head into the proper anatomical position and mark the position on the bone at the etched line labeled "MAX" (Fig. 33), or use the lateral fin as a point of reference (Fig.34).

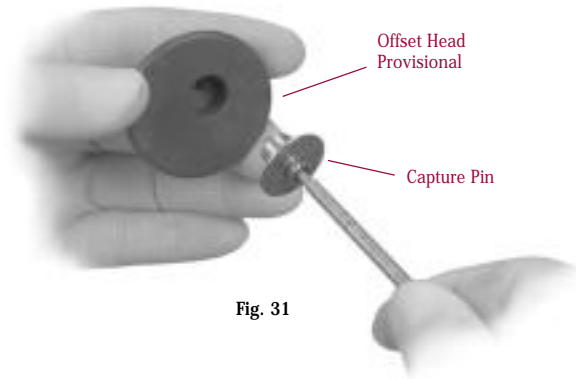


Fig. 31

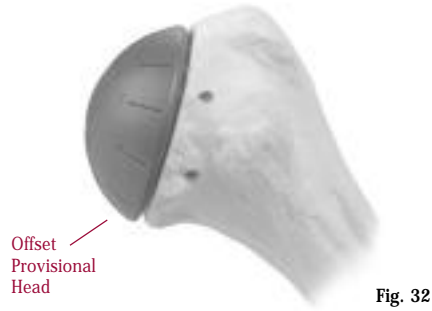


Fig. 32



Fig. 33

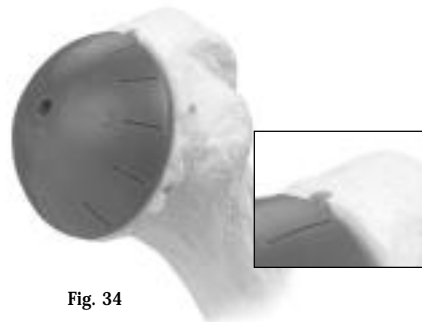
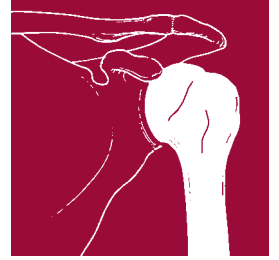
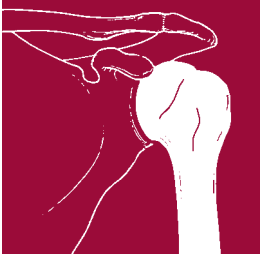


Fig. 34





EXPANDED GLENOID OPTIONS

As detailed elsewhere in this technique, glenoid and humeral preparation are accomplished separately. Therefore, there may be times when the prepared articular surface of the glenoid does not match the articular surface of the desired humeral head. When this occurs, the bi-colored provisionals must be used. This is necessary to match the articular surfaces of the selected components.

The color of the center bar (Fig. 35) of the Glenoid Provisional must always match the color of the Humeral Head Provisional. The following chart illustrates the range of glenoid sizes.














Fig. 35

GLENOID IMPLANTS/PROVISIONALS SIZING CHART

 zimmer		HUMERAL HEAD SIZES			
		40mm	46mm	52mm	56mm
INSTRUMENTATION COLORS	BLACK  BK/40	 BK/46			
	WHITE  WH/40	 WH/46	 WH/52		
	 BL/46	 BL/52	 BL/56		
 BLUE 4301-95-50					

Peripheral color corresponds to prepared glenoid size. Center bar color, of bi-colored provisional, corresponds to humeral head size.

For example, if white (46mm) instrumentation was used to size/prepare the glenoid, either a black (40mm), white (46mm) or blue (52mm) Humeral Head may be used. If a blue Humeral Head is selected (Fig. 36), remove the white WH46 Glenoid Provisional (Fig. 37) and replace it with the WH52 white with blue center bar Glenoid Provisional (Fig. 38).

The solid color glenoid provisional should be replaced with the appropriate bi-colored provisional for joint reduction and trial range of motion. Then remove the Provisional Head, but leave the Stem Provisional in place to help decrease bleeding while cementing the glenoid component.

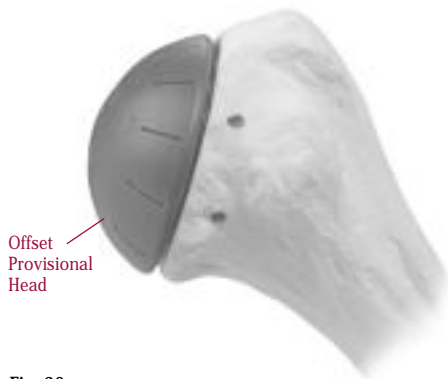


Fig. 36

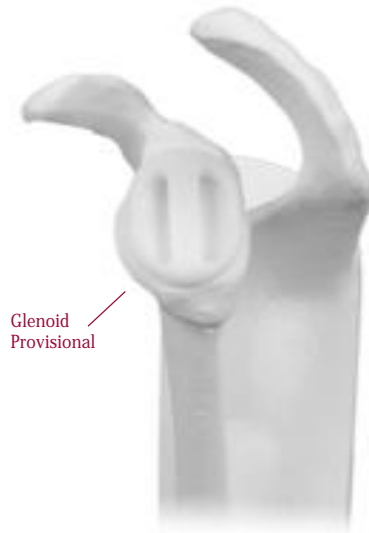

Fig. 37

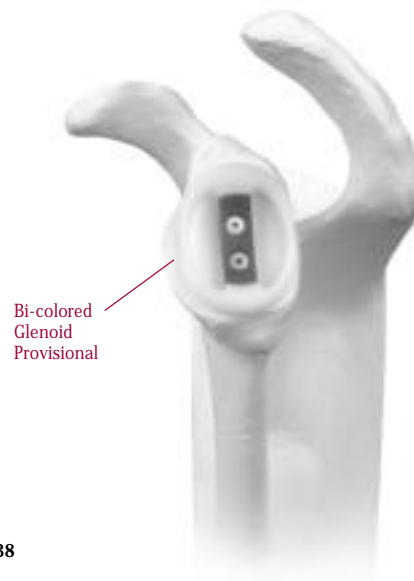
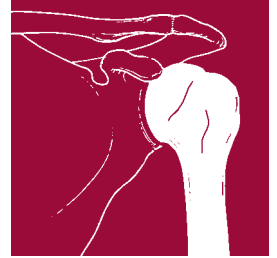

Fig. 38





IMPLANTATION

GLENOID COMPONENT

Remove the Glenoid Provisional and use pulsatile lavage, such as the Pulsavac® Wound Debridement System, to irrigate the glenoid vault. Coagulate any active bleeding, and dry the glenoid vault. If implanting a keeled glenoid component, insert a thrombin-soaked Keel Sponge to dry the vault (Fig. 39a).

Remove the Keel Sponge. Introduce cement into the keel slot or peg holes using a 60cc syringe, being careful that no cement is applied to the articular surface of the glenoid bone. Cement should be introduced early in the working time to facilitate pressurization into the cancellous bone bed. Then attach a Pressurizer Sponge to the appropriate Glenoid Sizer/Pressurizer (Fig. 39b) and pressurize the cement. When the Glenoid Sizer/Pressurizer is removed, some of the cement may adhere to the instrument and the sponge; however, most of the cement remains in the glenoid having been pressurized into the cancellous bone. Apply additional cement and repressurize. Finally, apply more cement before inserting the glenoid component. If desired, you may apply cement to the keel or pegs. Do not apply cement to the underside of the glenoid component.

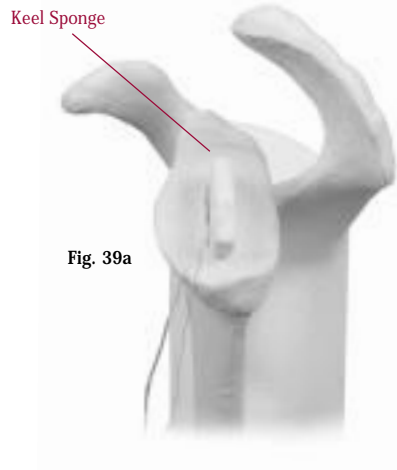
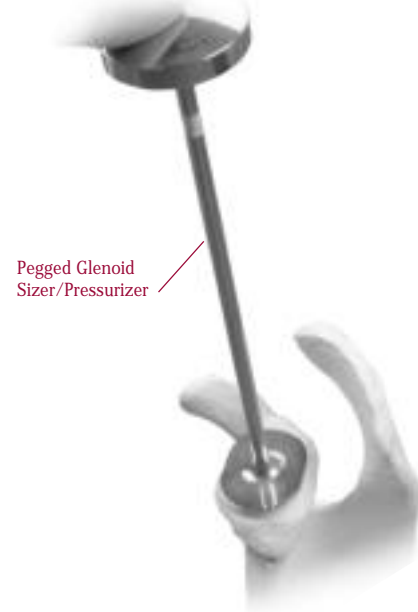

Fig. 39a




Fig. 39b



Keeled

Pegged

Prior to opening the glenoid implant, confirm that the component matches the glenoid provisional used in the trial reduction. Use the Glenoid Inserter to insert the component (Fig. 40). Then use the Glenoid Pusher to impact the component until there is complete contact with the perimeter of the glenoid (Fig. 41). Maintain pressure on the glenoid with the pusher or thumb until the cement has hardened. Be sure that the pressure remains centralized within the glenoid so that eccentric pressure is not applied during cement hardening. Remove excess cement with care.

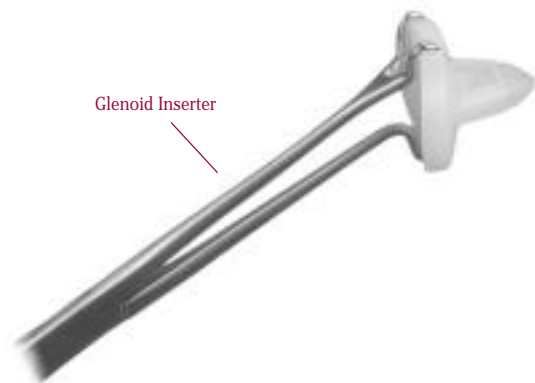


Fig. 40

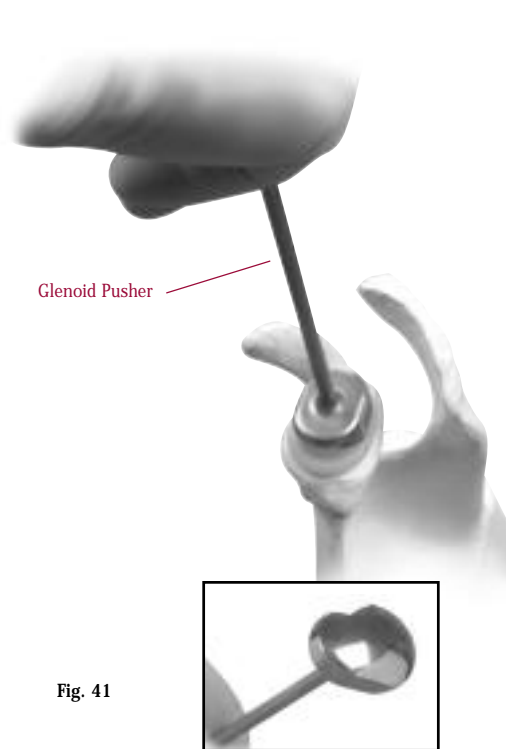
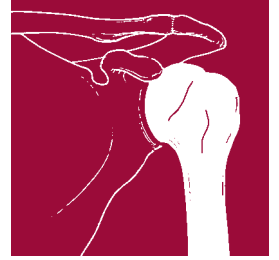
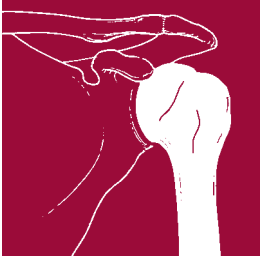


Fig. 41





HUMERAL COMPONENT

Use the Wrench handle through one of the holes to tighten the white plastic cap on the Humeral Stem Inserter/Extractor. Attach the inserter/extractor to the Humeral Stem Provisional and tighten the thumb screw. Apply the Slaphammer Weight to the inserter/extractor, and remove the Humeral Stem Provisional from the canal.

If countersinking of the humeral component is desired, assemble the Stem Collar Counterbore using the appropriate size stem extension to match the stem diameter chosen (Fig. 42a). Attach the Straight Driver to the counterbore (Fig. 42b) and insert the stem extension of the counterbore into the humeral canal (Fig. 42c). (Do not use the Angled Driver.) Using the Ratcheting T-handle, counterbore the resected surface

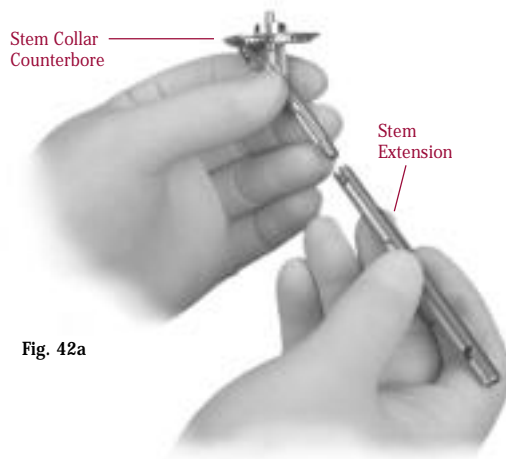
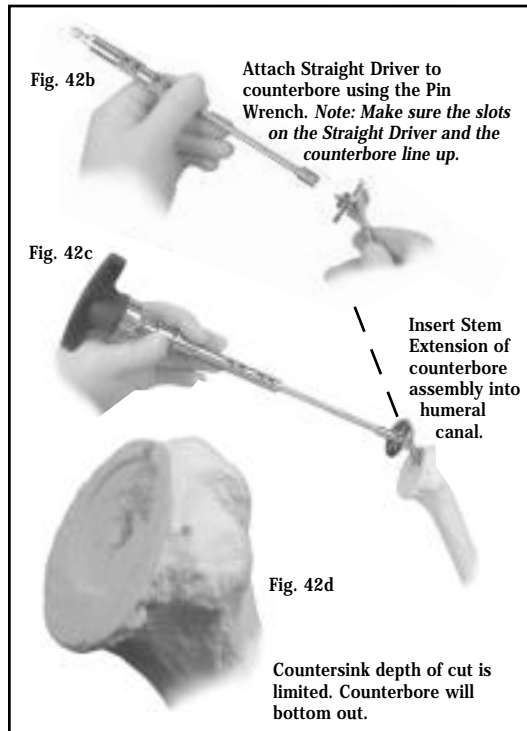


Fig. 42a



of the proximal humerus. The counterbore depth of cut is limited, and the Stem Collar Counterbore will bottom out (Fig. 42d). When removing the counterbore, do not pull up in line with the shaft of the driver. Instead, pull up in line with the axis of the humeral shaft.

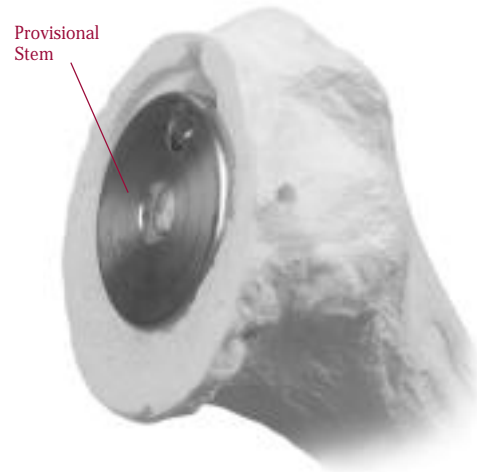


Fig. 43

Attach the Humeral Stem Provisional to the Humeral Inserter/Extractor and reinsert the provisional to ensure that the collar is completely countersunk (Fig. 43). Snap on the appropriate size Humeral Head Provisional. Then reduce the joint and check the fit on both the superficial and deep surfaces. Choose a humeral head so that, when in position, applied pressure will sublux the head about 50 percent of its diameter posteriorly and inferiorly, falling back into place when the pressure is released. A head that does not fill the capsule will dislocate over the glenoid rim, and one that overstuffs the joint will not allow this “50-50” laxity assessment. Pull the subscapularis muscle over the joint. If the fit is too tight, release the tendon as necessary. Often, releasing the subscapularis from the anterior labrum and capsule will provide sufficient mobilization to the neck of the humerus. Remove the provisional components and perform any necessary soft tissue releases.

Before inserting the final humeral component, drill four to five suture holes through the anterior neck of the proximal humerus. The drill holes should start superior just anterior to the bicipital groove and proceed inferiorly to the inferior aspect of the neck just in front of the midline. Place heavy number 2 braided nylon sutures with wedged-on needles prior to cement fixation. Each needle should progress from the outside cortex to the inside so that the same needle is used to place the sutures through the subscapularis tendon. By placing the subscapularis tendon more

medially against the neck of the humerus, the tendon is effectively lengthened because it does not have to be placed lateral to the lesser tuberosity. After the final humeral head prosthesis has been securely implanted, suture the subscapularis tendon inferiorly and repair it progressively to the superior sutures with the arm placed comfortably in 20 degrees to 30 degrees of external rotation. Place heavy nylon sutures into the anterior edge of the humerus for reattachment of the subscapularis tendon and muscle.

Cemented Technique Intraoperative Assembly

Insert canal sizers to determine the appropriate size cement restrictor plug. Then insert a plug one centimeter distal to the tip of the humeral stem.

Thoroughly clean and dry the canal. Inject cement into the humeral canal. Use a finger to thoroughly pack the cement. Use the Wrench handle through one of the holes to tighten the white plastic cap on the Humeral Inserter/Extractor. Attach the humeral component to the inserter/extractor, and insert the distal tip of the component into the canal (Fig. 44). Insert the two

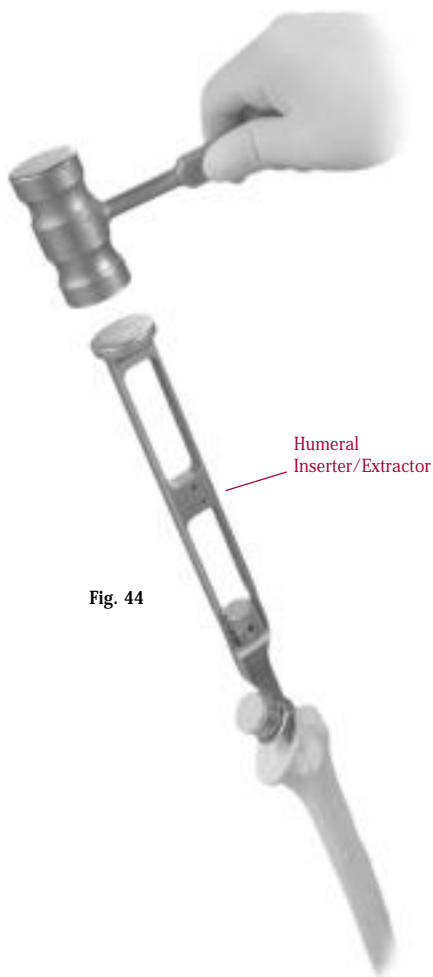


Fig. 44

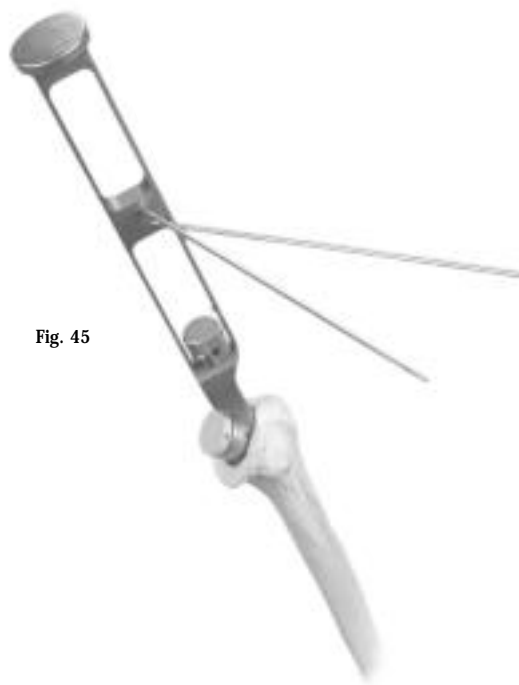


Fig. 45

Alignment Pins into the 20-degree and 40-degree holes of the inserter/extractor and check retroversion (Fig. 45). When properly aligned, fully insert the stem into the canal. Remove the Alignment Pins and impact the component with a few light taps of the mallet. Be sure that the collar of the component is seated flush on the cut surface of the humerus (Fig. 46).

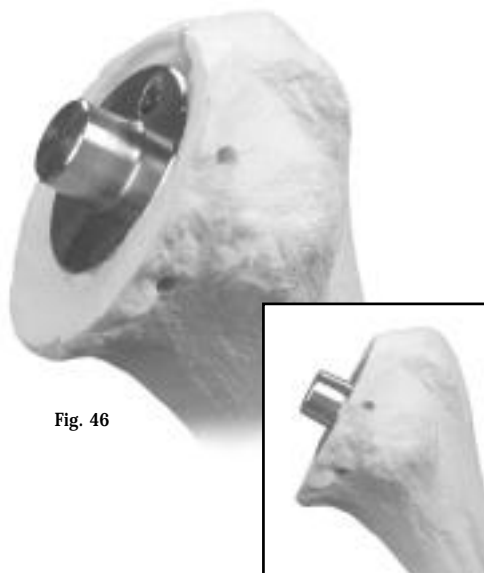
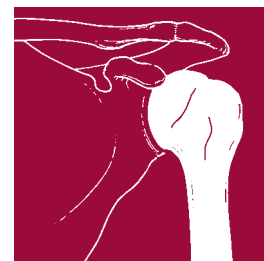


Fig. 46

Humeral component seated flush on the cut surface of the humerus.



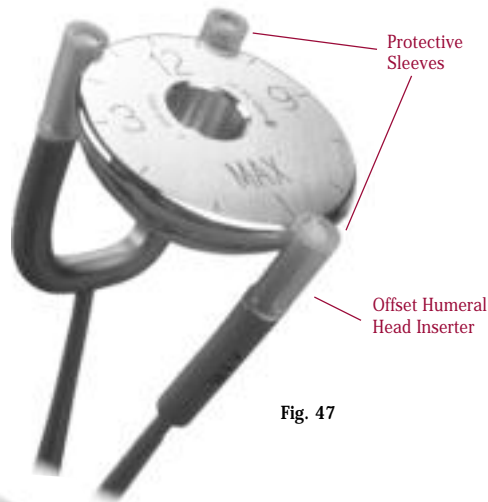
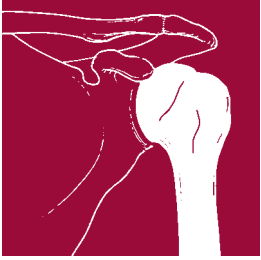


Fig. 47

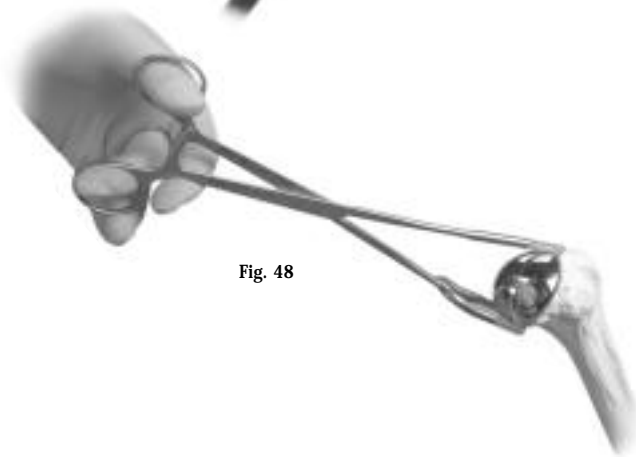


Fig. 48

The humeral head may be assembled to the implanted stem only after the cement has been allowed to fully cure. Remove the Capture Pin and place the Humeral Head Provisional on the humeral stem taper and perform a trial reduction to check subscapularis tension. The subscapularis, when reinserted, should allow for 30 to 45 degrees of external rotation, but sometimes with a chronically contracted rotator cuff, this is not possible. If the closure is too tight, a lower profile head may be used. Once the final head size has been selected, remove the Humeral Head Provisional.

Thoroughly clean the humeral stem taper. Attach the offset humeral head component to the Offset Humeral Head Inserter so the single prong is positioned at the "MAX" or previously marked indication (Fig. 47). Make sure protective sleeves are properly in place on the prongs of the Offset Humeral Head Inserter. Insert the final humeral head component so the single prong is at the mark made earlier (Fig. 48). Apply the Humeral Head Impactor to the head and impact it with a mallet. Make sure that the head is firmly attached. Then reduce the joint and assess stability.

Cemented Technique Back-table Assembly

With the offset implant "clock face" visible, place the humeral stem component so that the lateral fin is at the previously determined reference point. Place the assembled components into the Impaction Stand. Apply the Humeral Head Pusher to the head and impact it with a mallet (Fig. 49). Make sure that the head is firmly attached.

Insert canal sizers into the humeral canal to determine the appropriate size cement restrictor plug. Then insert a plug one centimeter distal to the tip of the humeral stem.

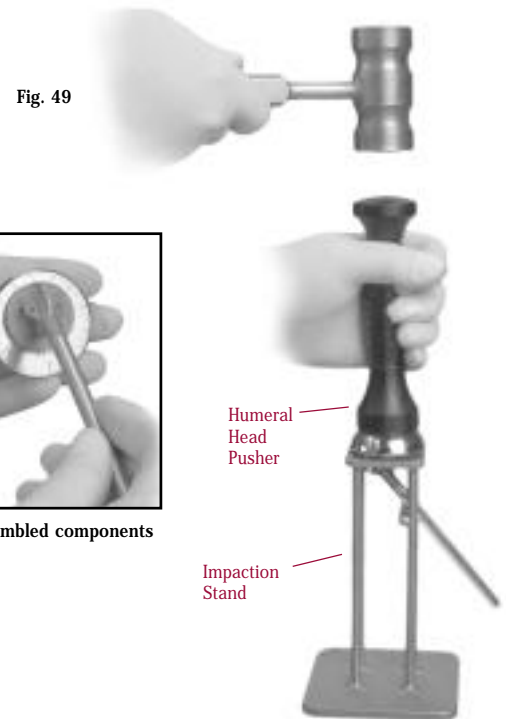


Fig. 49

Assembled components

Humeral Head Pusher

Impaction Stand

Thoroughly clean and dry the humeral canal. Inject cement into the canal. Use a finger to thoroughly pack the cement. Insert the assembled humeral component into the canal (Fig. 50). The final selection of stem size is a matter of surgeon judgement based on the preferred cementing technique. Be sure that the collar of the component is seated flush on the cut surface of the humerus (Fig. 51). Then reduce the joint and assess stability.

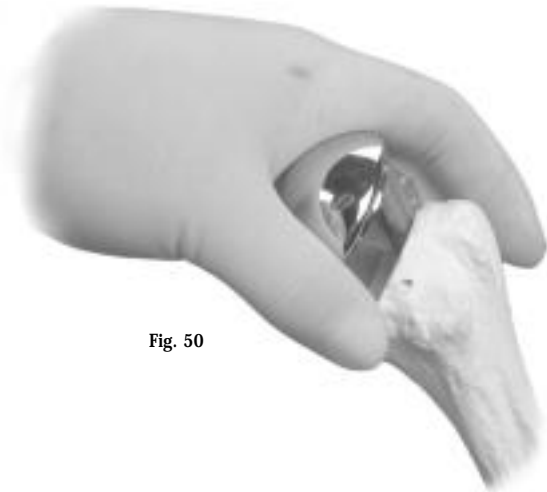


Fig. 50

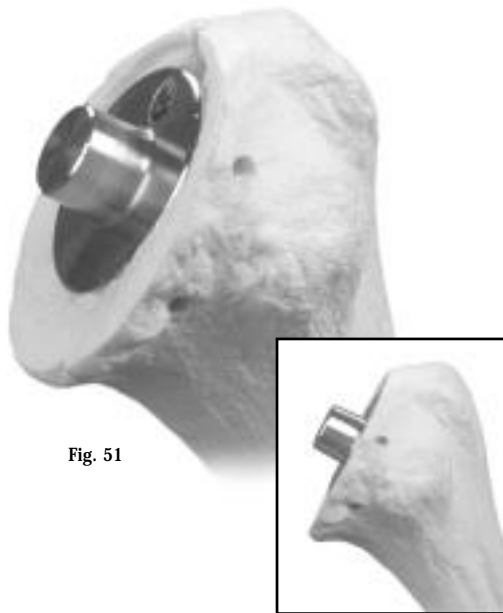


Fig. 51

Humeral component seated flush on the cut surface of the humerus.

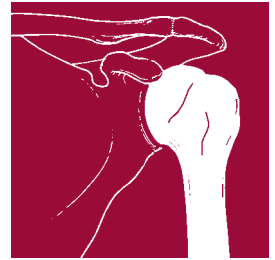Press-fit Technique

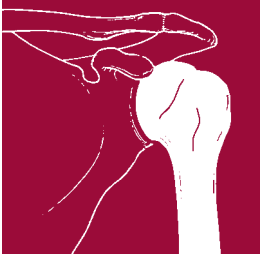
The humeral stem can be press-fit and sized to the reamed diameter. Attach the humeral component to the Humeral Stem Inserter/Extractor and insert the stem into the canal (Fig. 52). Insert the two Alignment Pins into the 20-degree and 40-degree holes of the inserter/extractor and check retroversion (Fig. 53). Impact the component with a few light taps of the mallet. Be sure that the collar of the component is seated flush on the cut surface of the humerus (Fig. 54).



Fig. 52

Fig. 53





Remove the Capture Pin and place the Humeral Head Provisional on the humeral stem taper and perform a trial reduction to check subscapularis tension. The subscapularis, when reinserted, should allow for 30 to 45 degrees of external rotation, but sometimes with a chronically contracted rotator cuff, this is not possible. If the closure is too tight, a lower profile head may be used. Once the final head size has been selected, remove the Humeral Head Provisional.

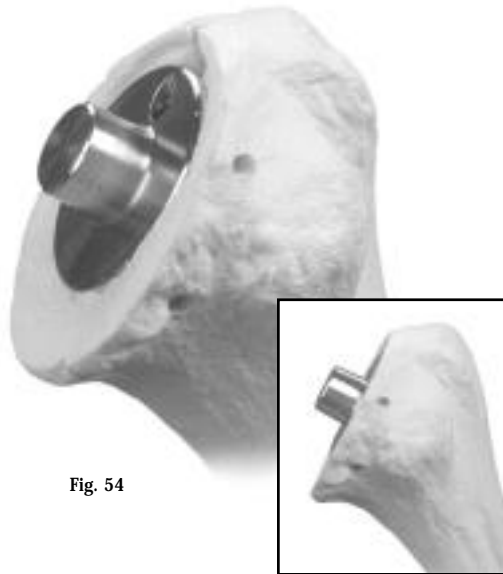


Fig. 54

Humeral component seated flush on the cut surface of the humerus.

Thoroughly clean the humeral stem taper. Attach the offset humeral head component to the Offset Humeral Head Inserter so the single prong is positioned at the "MAX" or previously marked indication (Fig. 55). Insert the final humeral head component so the single prong is at the mark made earlier (Fig. 56a). Apply the Humeral Head Pusher to the head and impact it with a mallet (Fig. 56b). Make sure that the head is firmly attached. Then reduce the joint and assess stability.



Fig. 55

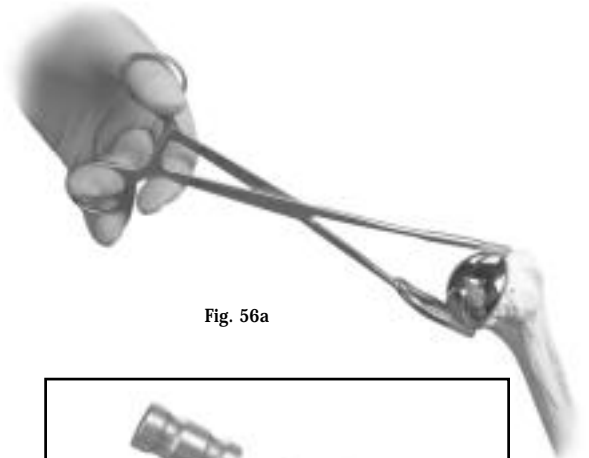


Fig. 56a




Fig. 56b

Apply the HumeralHead Pusher to the head and impact it with a Mallet

HUMERAL HEAD REMOVAL

Should a humeral head ever have to be removed, slide the Head Distractor between the collar of the humeral stem and the undersurface of the humeral head (Fig. 57). Firmly tap the end of the instrument to loosen the head. This instrument can be used to remove either provisional heads or implants.

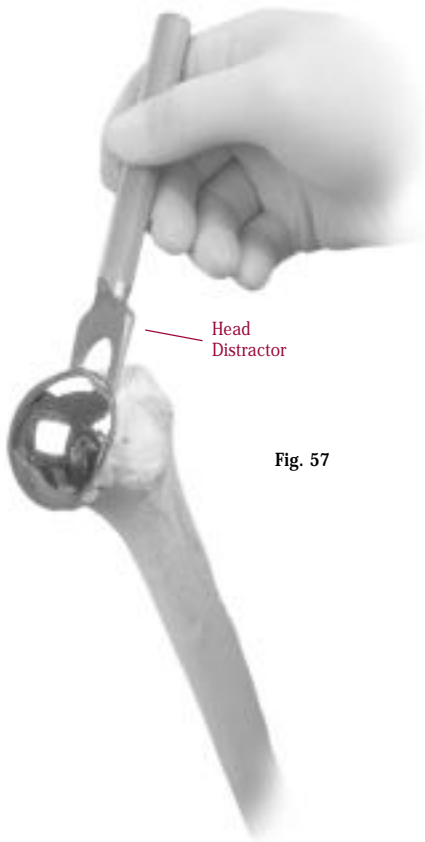
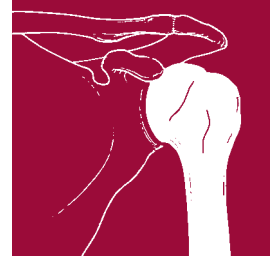


Fig. 57

CLOSURE

Irrigate the wound and, beginning inferiorly, reattach the subscapularis muscle to the sutures at the rim of the proximal humerus. Insert a Hemovac Wound Drainage Device, being careful to avoid the axillary nerve. Close the deltoid and the subcutaneous layers. Then close the skin.



POSTOPERATIVE MANAGEMENT

On the first postoperative day, the patient typically begins passive, assisted range of motion. This should include pendulum exercises in the erect position, assisted forward elevation exercises in the erect and supine positions, and external rotation exercises with a stick in the supine position with the arm slightly abducted. The patient is typically discharged at two to four days postoperative, but should continue exercises as an outpatient with goals of 140-degrees forward elevation and 40-degrees external rotation within two to three weeks. Further range of motion is progressively achieved with stretching exercises.

Active exercises are typically started after one to two weeks depending on the pathology. Active internal rotation should be avoided, however, as the subscapularis muscle has been repaired. After six weeks, more resistant strengthening exercises should be started. These exercises should emphasize stretching and balancing the range of motion. Strengthening is a secondary concern that need not be achieved until several months postoperatively.







