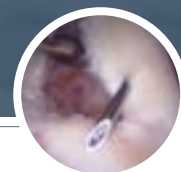

# Arthroscopic Soft Tissue Biceps Tenodesis with ORTHOCORD™ Suture



**JEFFREY S. ABRAMS, M.D.**

*Orthopaedic Surgeon  
University Medical Center at Princeton  
Princeton, NJ*



## Arthroscopic Soft Tissue Biceps Tenodesis with ORTHOCORD™ Suture

JEFFREY S. ABRAMS, M.D.

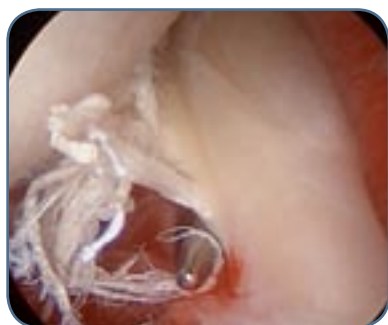### TECHNIQUE OF BICEPS TENODESIS

The long head of the biceps is uniquely located along the rotator interval and supported in place by a combined pulley-ligament system and insertion of the rotator cuff. As a result, this tendon can be injured either due to instability of the tendon out of the groove, partial tears, or a complete tear. These tears and instability can be associated with either an intact rotator cuff, partial-thickness tears of the rotator cuff, or a full-thickness torn rotator cuff. In cases where the rotator cuff pathology is minimal, a biceps tenodesis can be performed incorporating the long head of the biceps tendon into the rotator interval to pre-

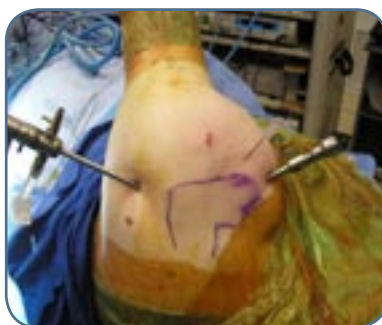vent the distal deformity that is seen with tenotomy. The following is a biceps tenodesis technique of soft tissue to soft tissue in cases where the rotator cuff is intact.

### POSITIONING AND PORTALS

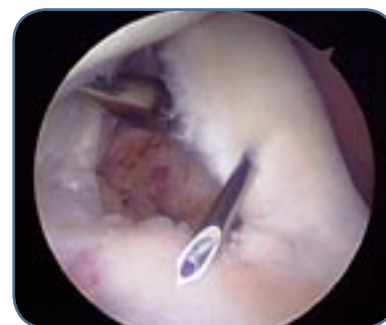The patient is positioned in the lateral decubitus position. Portals for the procedures are as follows. Three portals are used for the procedure. A standard posterior viewing portal is created. This is followed by an anterior portal which is adjacent to the anterior edge of the acromion, and finally a lateral portal 3cm off the lateral border of the acromion for bursectomy and knot tying.



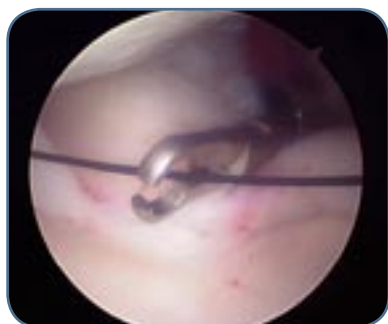
**FIGURE 1.** This is an articular view of a left shoulder with an advanced tear in the substance of the long head of the biceps tendon.



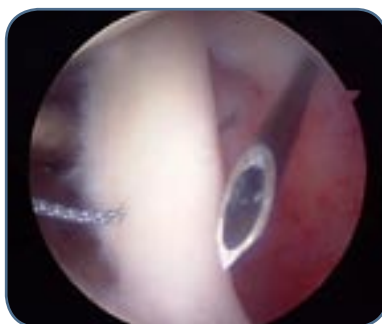**FIGURE 2.** Outside view of a percutaneous needle placement that pierces the rotator interval and long head of the biceps.



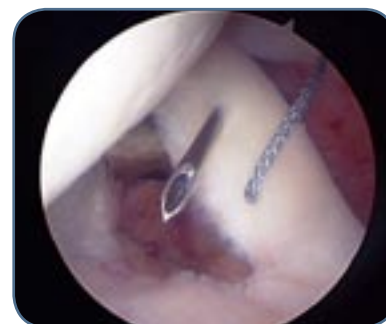**FIGURE 3.** This is an intra-articular view of the spinal needle with the trocar removed piercing the long head of the biceps tendon.



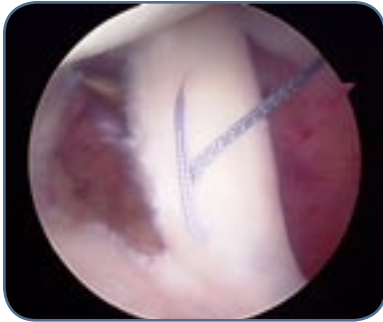**FIGURE 4.** The shuttle is introduced through the hollow needle and retrieved out through the anterior cannula. This shuttle is used to shuttle a stitch of ORTHOCORD Suture.



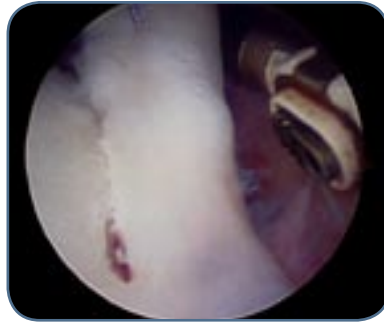**FIGURE 5.** The spinal needle has been reintroduced, allowing for retrieval of the shuttle through the anterior cannula and shuttling the braided ORTHOCORD Suture originally placed, creating a transverse mattress stitch.



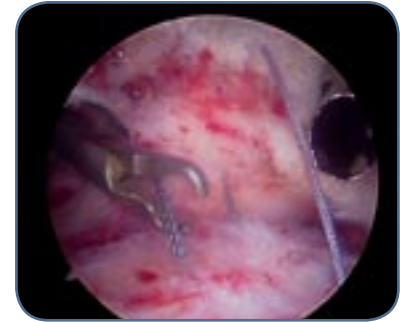
**FIGURE 6.** The spinal needle is reintroduced above prior stitch to introduce the shuttle followed by a second stitch.



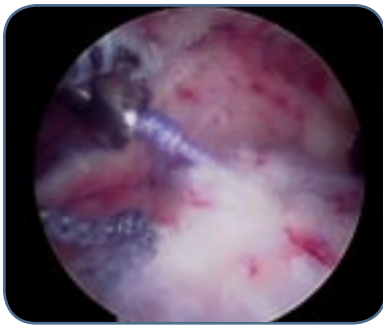
**FIGURE 7.** The stitch is retrieved after an additional needle placement, creating crisscrossing sutures similar to a Mason-Allen effect.



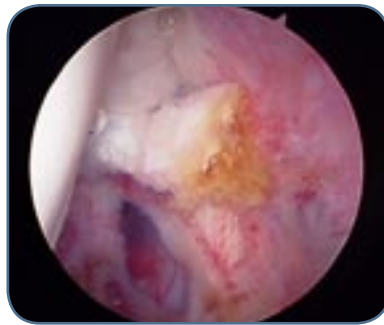
**FIGURE 8.** Tenotomy of the long head of the biceps is performed next to the insertion on the superior labrum with the VAPR® S90 device.



**FIGURE 9.** The Scope is placed in the bursa and colored sutures are paired.



**FIGURE 10.** The sutures are retrieved and tied under direct visualization within the bursa.



**FIGURE 11.** The biceps stump of the long head of the biceps is well secured against the undersurface of the rotator interval-supraspinatus junction, thus completing the biceps tenodesis.

### **POSTOPERATIVE COURSE**

The arm is placed in a sling for 3-weeks. Gentle pendulum exercises, active assisted external rotation and grip strengthening exercises are begun. After 3-weeks, the sling is removed and assisted forward elevation is begun. Strength and resistance exercises are begun at 8 weeks. Return to full activity at 3 months.

## ORTHOCORD™ HIGH STRENGTH ORTHOPAEDIC SUTURE

CordCutter	214646			
	<i>with MO-6 Tapered Needles</i>	<i>w/MO-7 Tapered Needles</i>	<i>w/OS-6 Reverse Cutting Needles</i>	<i>without needles</i>
ORTHOCORD Violet	223102	223104	223103	223105
ORTHOCORD Blue				223111
ORTHOCORD Violet /Blue	223115	223114	223116	223113

## VAPR® SYSTEM

VAPR S90	225370			
VAPR SIDE ELECTRODE	225301			